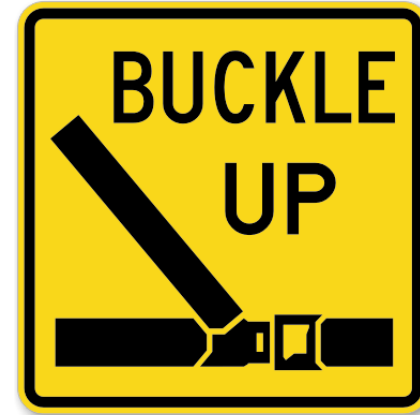


Imaging in Blunt Trauma



1. How do you decide which patients with abdominal trauma need a CT?
2. Do you order chest CTs on stable patients with focal chest wall tenderness and a normal AP chest X-ray?
3. Do you pan scan in stable patients? If so, when and why?
4. Do you have clinical situations in which a negative FAST exam precludes the need for a CT?

